

2016

A Retrospective Surgical Experience Regarding Open and Laparoscopic Procedures of the Hepatic Hydatid Cyst with an up to Date Complete Review of the Literature And a Focus On Original Romanian Techniques

Diana Moldovan

MedLife S.A., rarinca.diana@gmail.com

Cosmin Alec Moldovan

Titu Maiorescu University of Bucharest, moldovan.cosmin@gmail.com

Laurentiu Ungurianu

Witting Clinical Hospital of Bucharest, ungurianulaurentiu@gmail.com

Dan Florin Ungureanu

Titu Maiorescu University of Bucharest, fdungureanu@gmail.com

Follow this and additional works at: <https://scholar.valpo.edu/jmms>



Part of the [Medical Sciences Commons](#), and the [Surgery Commons](#)

Recommended Citation

Moldovan, Diana; Moldovan, Cosmin Alec; Ungurianu, Laurentiu; and Ungureanu, Dan Florin (2016) "A Retrospective Surgical Experience Regarding Open and Laparoscopic Procedures of the Hepatic Hydatid Cyst with an up to Date Complete Review of the Literature And a Focus On Original Romanian Techniques," *Journal of Mind and Medical Sciences*: Vol. 3: Iss. 2, Article 10.

Available at: <https://scholar.valpo.edu/jmms/vol3/iss2/10>

This Research Article is brought to you for free and open access by ValpoScholar. It has been accepted for inclusion in Journal of Mind and Medical Sciences by an authorized administrator of ValpoScholar. For more information, please contact a ValpoScholar staff member at scholar@valpo.edu.

A Retrospective Surgical Experience Regarding Open and Laparoscopic Procedures of the Hepatic Hydatid Cyst with an up to Date Complete Review of the Literature And a Focus On Original Romanian Techniques

Cover Page Footnote

This material is part of a larger study of a PhD studies thesis, currently under development by Rarinca (Moldovan) Diana-Adina, M.D., Ph. D. Student at the Titu Maiorescu University of Bucharest, Faculty of Medicine with Prof. Ungureanu Florin Dan as thesis coordinator. All authors have read and approved the final manuscript and declare no conflicts of interest.

A retrospective surgical experience regarding open and laparoscopic procedures of the hepatic hydatid cyst with an up-to-date review of the literature and focus on original Romanian techniques

¹*Diana Moldovan*, ²*Cosmin Alec Moldovan*, ³*Laurențiu Ungurianu*, ²*Dan Florin Ungureanu*

¹MedLife S.A., ²Titu Maiorescu University of Bucharest, ³Witting Clinical Hospital of Bucharest

Abstract

Introduction: Even though the development of the recent anti-parasitic drugs has led to a high degree of efficiency, surgical treatment still remains the gold standard for a number of conditions. **Material and method.** The authors discuss a series of 90 cases in a multicenter and retrospective analysis that stretches over 20 years. **Results and discussions.** These cases have been diagnosed and treated – through different surgical methods, both classical and laparoscopic – for hepatic hydatid cysts. The paper also presents a short review of the major types of surgical procedures cited in the international literature, with a specific focus on the advantages brought by Romanian innovations in this field. **Conclusions.** Even though the classical open approach still assumes the first place among surgical procedures, modern laparoscopic techniques have earned a much appreciated place in providing positive results based on long-term assessment, with virtually no or only minor complications. In this regard the Romanian school of surgery has offered a significant contribution to this field.

Keywords: hydatid cyst, open, laparoscopic surgery, retrospective study, original Romanian techniques



Introduction

Although some authors recommend, in parallel with the surgical treatment, administration of drugs based on benzimidazole, for up to 2 or 3 months, with a constant imaging monitoring and with the screening of hepatic tests, the surgical treatment represents, basically, the only real choice for reaching a disease-free status, in a compact timeframe.

In essence, surgical therapy has 3 main objectives: removal of the cyst, resolving the remnant cavity, and the treatment of the biliary complications, if present. Therefore, the surgical intervention should be staged in two parts: the hepatic one, followed by the biliary stage (1).

Materials and Methods

In this paper we discuss our experience concerning only the posthydatid remaining cavity based on 90 patients with central singular or multiple locations of the parasite, for which we performed a variety of surgical techniques, some considered classic, others being new and innovative. This large number of cases was achieved during 20 years of surgical experience (from 1995 to 2015) that covers the activity from both Caritas Clinical Hospital and Witting Clinical Hospital, during the latter years adding the benefits of laparoscopic surgery as well.

A short review of the current literature.

Since publications were first available in the scientific community regarding surgical treatment of the hydatid cyst, we report keypoints marking the history of surgery and representing milestones:

1. Chistotomy (Recamier, 1825) represented by the incision and total evacuation of the parasite. The stage for resolving the pericyst has several variants:

- a. Methods that leave the adventice “in situ”, as a whole: marsupialization, chistoraphy and chisto-digestive anastomosis.
- b. Methods in which the adventice is partially excised: the Lagrot-Mabit partial perichistectomy and the large or subtotal perichistectomy which in fact extends out towards a total perichistectomy;
- c. Methods in which the adventice is excised in full: actually a total chistectomy.

2. Chistectomy (Napalkov, 1925) with its following variants: the “ideal” perichistectomy (Pazzi, 1902), the resection of the cysts and the chistectomy that is included in the standard hepatectomies. Later on the laparoscopic procedure joined this list, being first reported in 1995 (2) and also later in a larger retrospective study in 2010 by Misra M. et al (3).

Basically two main types of procedures are used: incisions and partial resections of the pericyst (Mabit – Lagrot) – when the cyst is placed at a superficial layer and therefore its resection generates a cavity that needs to be addressed; and extirpation of the whole cyst, without a previous chistotomy (the so-called ideal perichistectomy).

However, resolving *the remnant cavity* has undergone a series of steps, too, including:

- marsupialisation;
- transomphalic extraperitoneal perichistectomy (D. Burlui, 1968);
- the laparoscopic variant of the above procedure (D. Ungureanu, 2001);
- the extraperitoneal and transligamentary drainage of the remnant cavity through the round ligament transposition (D. Ungureanu, 2002)
- the extraperitoneal surgical drainage or direct transpleural (Clairmont);
- laparoscopic extraperitoneal direct perichistotomy (D. Ungureanu, 2011);
- perichistoraphy invaginated as much as possible in order to reduce the residual space, whether or not associated with a GUED tunneling for biliary fitulae (T. Stoica);
- chisto-digestive anastomosis after desoperculation with different segments of the digestive tube (Lagrot procedure);

Table 1. Distribution and types of surgical procedures performed.

TYPE OF PROCEDURE	No. of Cases
Classical transligamentary drainage	64 cases
Laparoscopic transligamentary drainage	5 cases
Round ligament transpositions, transligamentary drainage	2 cases
Direct laparoscopic perichistostomy	6 cases
Hepatic segmentectomy	11 cases
Ideal perichistostomy	2 cases
TOTAL	90 cases

Results

Regarding the types of operations performed, the full array of surgical techniques involved can be seen

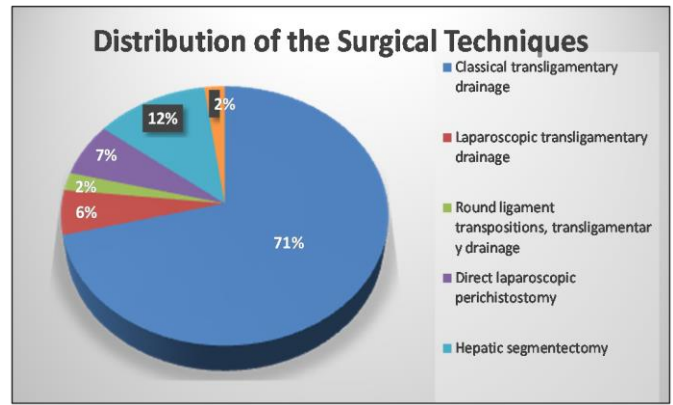


Figure 1. The graphical distribution of all surgical techniques used in our study. Note that the classical open approach is still dominating the landscape of surgical procedures.

at a glance in Table 1, and Fig. 1. The procedures in question range from the classical transligamentary drainage to the novel and revolutionary procedure of the direct laparoscopic perichistostomy, first designed and implemented into surgical practice by Ungureanu D. in 2011.

Extraperitoneal transomphalic drainage of the posthydatid hepatic restant cavity by open and laparoscopic approach

First, no bleeding or other operative complications related to this specific method has occurred. In fact, the possible and probable vascular risks of penetration of the hepatic tissue with the drainage instrument are more likely of a theoretical nature. Postoperative ultrasound and C.T. scan controls did not reveal development of intraparenchymal hematoma, as a result of drainage installation. There are however several associated conditions, which may determine a loss of elasticity of the hepatic tissue and may implicitly involve the risk of serious bleeding when the parenchyma is penetrated by the instrument. Such conditions

include hepatic cirrhosis, hepatic fibrosis, hepatic metastases or heart failure stasis. These are absolute contraindications of trans-omphalic drainage, in any of its variants.

Secondly, since the transomphalic drainage is totally extraperitoneal, without any contact whatsoever with the peritoneal cavity, any leak or loss of biliary fluid will take the same extraperitoneal route. There were no postoperative complications specific to other types of external drainage of the hepatic remaining cavity, such as subphrenic abscesses, choleperitoneum or external biliary fistulae.

Nevertheless, the communication of the hepatic cyst with the biliary tree occurred in 42 out of 48 patients. The draining fluids have become bilious and purulent some days after surgery and did not change its aspect until drainage has fully ceased and the drainage tube was removed. The drainage flow, which at first had ranged daily between 100 and 300 ml, gradually decreased completely, spanning the time period from 28 to 90 days after surgery.

Transomphalic drainage was suppressed after an average of 38 days. Some patients were discharged with the drain in place, covered by dressing, so the duration of postoperative hospitalization varied between 14 and 35 days, with an average of 16 days.

Associated colecistectomy decreases the rate of biliary complications to 0%. A relapse of the hepatic hydatid cyst was not related following the cases between 1 - 6 years.

Laparoscopic transligamentary drainage of the residual hepatic cavity, original technique imagined by D. Ungureanu

Extraperitoneal transligamentary drainage of the hepatic cavity formed after a hydatid or a hepatic abscess are drawn out, allows the disappearance of the residual cavity by placing an exteriorized drain tube through the round ligament in such a way that its route will be situated outside the peritoneal cavity and will have no contact with it (4).

Having a complete extraperitoneal route eliminates from the beginning any peritoneal complications, and the abdominal and diaphragmatic pressure will flatten and allow fibrosis of the newly formed cavity.

D. Burlui was the first to perform extraperitoneal draining of the hepatic cavity by classic means, publishing this technique in Romania in 1970 and internationally in 1971. This technique consisted of restoring the permeability of the omphalic vein and placing the drain tube on its route (5).

Firstly named “transomphalic pericystectomy”, the technique consists of draining the residual cavity after surgical evacuation of a hepatic hydatid, through the omphalic vein, following a complete extraperitoneal route in order to avoid any peritoneal complication.

The same practitioner performed the same type of drainage through the round ligament, without including the omphalic vein and deduced that these two methods are identical regarding their function and evolution, so this type of drainage is known in the literature as transligamentary drainage.

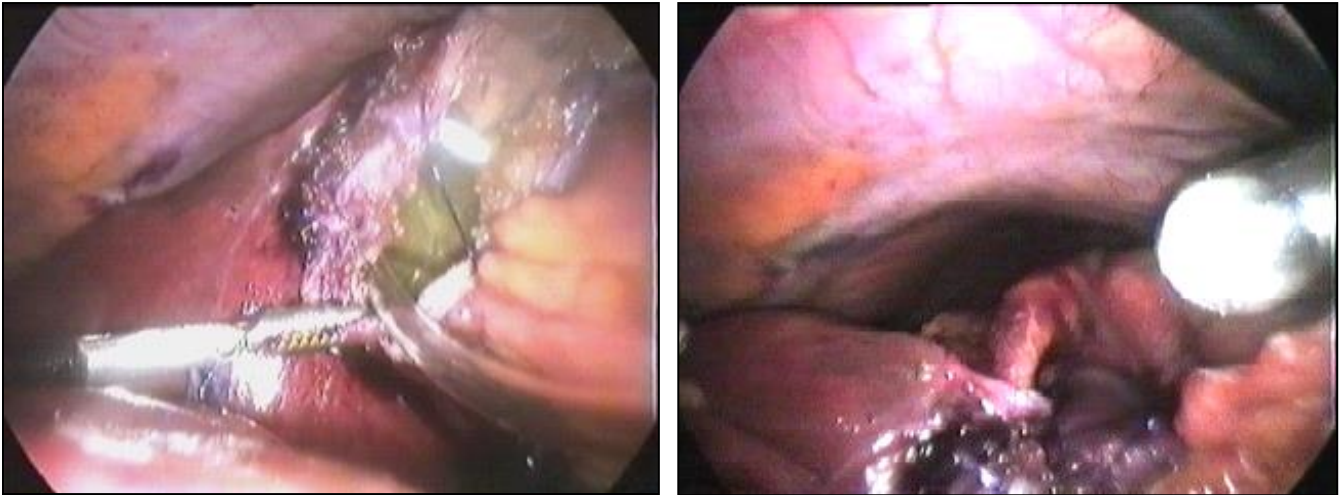


Figure 2. Key aspects of the procedure. From right to left: after fixing in place, with separate stiches, the ligament to the left side of the cystotomy, a drainage tube is inserted through the round ligament; the final aspect of the montage.

The laparoscopic alternative diminished postoperative suffering and shortened the recovery time, but has no influence on the draining period and offers a series of advantages to this technique which justifies its continuance. That is, Prof. Ungureanu and his team managed to develop and implement it for the first time in 2000, with 5 cases in this series, producing good results on long term follow-up (Fig. 2). The purpose of this method is to avoid whatever peritoneal complications that other current methods cannot avoid.

The laparoscopic method is entirely different from the classic method, having its own features, including an intermediate time imposed by several rules, which add a number of advantages, being both effective and risk-free (6, 7).

Transligamentary drainage through transposed round ligament, an original technique imagined by D. Ungureanu

Extraperitoneal transligamentary drainage of the postoperative hydatid cavity or hepatic abscesses through transposed round ligament detached from the liver represents a derived technique from the

transligamentary drainage of the residual hepatic cavity after the removal of a hydatid or a hepatic abscess, as imagined by D. Burlui. This procedure allows the exteriorization of the drainage tube through the transposed round ligament in such manner that the drain tube will have a strictly extraperitoneal route.

For the same purpose, D. Burlui imagined the transomphalic and transligamentary versions of drainage, and these methods require an intact round ligament with normal insertion at both ends.

There are situations when sectioning the round ligament was necessary in order to widen the view or when the ligament was sectioned in prior interventions or when the round ligament was required for consecrated surgical procedures. For these situations there is the possibility of extraperitoneal drainage through the transposed round ligament, detached from the liver and implanted on the anterior hepatic edge of the incision that allowed the evacuation of the hydatid or the abscess. Effectiveness and no peritoneal

complications are possible if the ligamentous blunt that includes the drain tube is hermetically closed.

Transomphalic or transligamentary drain in classic manner uses the intact round ligament, with normal insertion at both ends, representing the future structure of externalization of the drain tube, thus having a complete extraperitoneal route. This type of externalization will not allow biliary or liquid loss in the peritoneal cavity, avoiding any peritoneal complication. However, there are situations when sectioning the round ligament was necessary in order to widen the view or when the ligament was sectioned in prior interventions or when the round ligament was required for consecrated surgical procedures, like axial drainage of the common biliary duct, round ligament cardiopexy or common biliary duct plasty.

On the other side there are a series of complicated communicant or suppurated hydatids, real hepatic abscesses, associated with general mood alterations in elderly or immunocompromised patients, where radical methods may result in important excisions of functional hepatic parenchyma or where the biological resources of the patient do not allow a radical intervention. In these cases, where the indication of drainage occurs and the round ligament was used in an anterior intervention, there is the possibility of using an

extraperitoneal trans-ligamentary drain through transposed round ligament. This type of drain is recommended due to its ultraconservative nature regarding the use of hepatic tissue. Because it is not an aggressive technique, it is easy to tolerate even in extremely serious cases and it allows no postoperative complications.

It is exactly in these extreme conditions, when the opportunity of a transligamentary drain is assessed as a simple and efficient solution that supports such a technique that allows using a round ligament, even though more or less deteriorated. Without launching into detail, we emphasize that this technique avoids penetrating hepatic tissue with the biliary stent, making it risk-free in our opinion even if, theoretically it has a degree of aggression.

The technical procedure implies draining of the residual hepatic cavity, through an extraperitoneal route that does not communicate with the peritoneal cavity in order to avoid any abdominal postoperative complication and through the transposed round ligament detached from the liver. The process of transposing the round ligament detached from liver respects the principle of the method and widens the area of usage for this type of drain for any hepatic localization of the precedent resting cavity (Fig. 3).

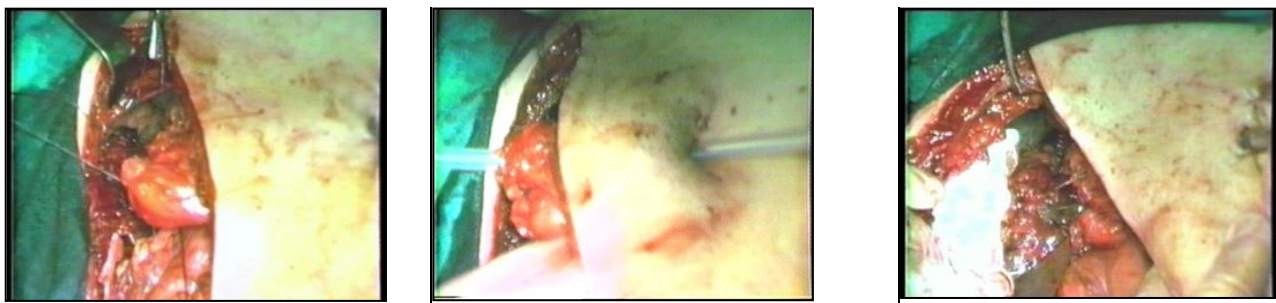

Figure3. Some of the technical aspects involed in the procedure. From right to left: sectioning the round ligament near its hepatic insertion, crossing the drainage tube through it and fixing the free end of the ligament to the chistectomy.

The procedure of transligamentary drainage through transposed round ligament avoids surgical risks that any other method or surgical technique involves, like hepatic resection, pericystico-digestive anastomosis or ideal pericystectomy, in a given situation in which the round ligament was sectioned in an anterior intervention and the surgical solution is urged.

Direct laparoscopic transparietohepatic pericystostomy, original technique imagined by D. Ungureanu

This method is a complete novelty in the landscape of the surgical procedures addressing hydatid cyst treatment. Prof. Ungureanu and his team imagined, designed and implemented this procedure for the first time in 2011, and since then there have been 5 cases, all with a very good clinical outcome.

Axial drainage of the exteriorized transparietohepatic biliary channel through the right hepatic lobe and then through the liver tissue of the right hepatic lobe at the abdominal wall, described by Burlui, is well known in the world of surgery. The only criticism of this type of drainage is the short portion of the drainage tube, between the liver and abdominal wall crossing the right subfrenic space, transperitoneal paths which allows supplying the peritoneal cavity with biliary purulent-leakages belonging to the remaining posthidatic cavity, which exposes the risk of a right subfrenic abscess. This result can be countered by associating a

permanent right subfrenic drainage placed in the vicinity of the hepatic breach subfrenic as emergent to the drainage tube, at the right subfrenic level.

On some occasions, we have witnessed the creation of a hepatoparietal symphysis that by joining the hepatic capsule at the parietal peritoneum of the abdominal wall around the drainage tube, to prevent biliary-purulent leakage towards the peritoneal cavity, and gives this type of transperitoneal drainage, the quality of being totally extraperitoneal, which virtually abolishes the risk of peritoneal complications.

We proceeded to install this type of transparietohepatic drainage at the hepatic posthidatic remaining cavity, twice through this classic way, then we set up this laparoscopic technique for this drainage that was executed in 5 cases with remarkable results.

Anatomical conditions necessary for optimum installation of this type of drainage are mandatory the hepatic headquarters of the hydatid cyst in the lateral segments of the right liver, the VIth, VIIth and VIIIth segments and the chance of externalizing the drainage tube through the abdominal wall, below the tenth rib, knowing that the diaphragmatic-rib sinus never descends below the tenth rib. Even when hydatid cyst is located in VIIIth segment, cystotomy can be performed at the caudal pole of the hepatic cavity, which will facilitate both drainage of the remaining cavity, and the pericysto-parietal tightening, at the abdominal wall below the Xth rib.

The ideal indication for this technique is spacious hydatid cysts located in the VIth and VIIth segments, which deform the abdominal wall or the location in lateral segments of the right liver, in a patient that is also presenting a hepatic ptosis.

This way the remaining cavity is opened to the abdominal wall, with a technique almost identical with the cholecystostomy technique, both of which can be performed laparoscopically today (8).

Discussion

Regarding the extraperitoneal transomphalic drainage of the posthydatid hepatic restant cavity by open and laparoscopic approach, concerning the hepatic hydatid cysts, the drainage of the remaining cavity by the round ligament was possible for most of the location of the parasite; sometimes double drainage is actually less favorable for the segments VI and VII, too far situated, for which we prefer the transparietohepatic drainage or the pericystoresection (9). With regard to the transparietohepatic variant, the main goal is to have the drain leave the hepatic parenchyma at the convex surface of the liver, crossing on its way to the abdominal wall, the right subphrenic space (10).

Regarding the laparoscopic transligamentary drainage of the residual hepatic cavity, the advantages of this technique are applicable to the ones acquired by classical means:

- setting up a hepatic cavity drainage that has a strictly extraperitoneal route and does not have any contact with the peritoneal cavity in order to avoid postoperative complications
- avoiding surgical risks that any other surgical method or technique will incur (hepatic resection, pericystic-digestive anastomosis or ideal pericystectomy);
- the feasibility of this risk-free method in so called “dangerous” hepatic locations of the hydatid, especially in the central or dorso-cranial segments, where other methods could fail;
- it reduces and allows fibrosis of the residual cavity until it disappears due to abdominal pressure and diaphragmatic pressure during inhale;
- along with reducing the cavity and its fibrosis, it allows biliary fistula remission;
- postoperative radiologic check with iodate tracers will force residual cavity reduction through fibrosis, in the same time with the effects of abdominal and diaphragmatic pressures.

Of course, this type of approach also includes the specific advantages of the laparoscopic technique, which are:

- the possibility of evaluating the anatomic points through imaging, like the topography and extension of the cyst, its exteriorization at the hepatic surface, the existence of peri-cystic adhesences, the round ligament generosity, risk and opportunities for transligamentary drainage

appreciation or the option for a more convenient technique;

- avoiding large incisions and their postoperative complications;
- avoiding postoperative suffering and analgesic medication;
- reducing the recovery time and specific therapeutic measures: antibiotic drugs, Fraxiparine, perfusive solutions, drugs with hepatic affinity, essential amino acids, sedatives or Albendazole (11);
- avoiding intraoperative dissemination of the hydatid content and the prophylaxis of peritoneal drawbacks by minimal removal of the cyst and by using a powerful suction tube;
- the possibility of intraoperative visualization of the biliary fistulas in the residual cavity and their interception;
- reducing the hospital stay although the remittal of drainage is not influenced by laparoscopic interventions. After a short introduction, drain carrying patients can monitor the drain on their own, without affecting the quality of life;
- social and professional readmission, reducing sick-leaves and the postoperative period of suffering;
- without affecting the tenet of the method, the laparoscopic way is entirely different from the classic method, having its own features and intermediate times imposed by several rules.

As for the transligamentary drainage through transposed round ligament, this technique has some important advantages worth mentioning:

- Its most important quality is the complete extraperitoneal route, even though the free head of the round ligament is re-implanted on the hepatic edge.
- The free cranial head of the round ligament can be reinserted anywhere on the anterior edge of the liver or on the anterior segments of the right or left liver, allowing the approach for multiple localization of the hydatids and hepatic abscesses.
- In this way biliary or liquid losses in the peritoneal cavity are avoided, excluding the peritoneal complications that will involve any other type of drainage or procedure.
- Even if it is simple to perform, the procedure implies complete sealing of the assembly, important for avoiding peritoneal complications.
- Postoperative evolution of the presented cases is identically superposed over the evolution of the cases in which classic surgery was performed, and this outcome is confirmed by repeated radiologic investigations with contrast media of the remaining cavity.
- This technical procedure also completes the classic method when, for various reasons, the integrity of the round ligament is compromised, but especially when the localization of the abscess, local or general complications, and the

general mood of the patient do not allow another serious intervention.

- This technique avoids penetrating the hepatic parenchyma with the metallic instrument on its route that previews the future externalization of the extraperitoneal drain; furthermore this procedure is both simple and riskless, even if, theoretically, it has some degree of aggression.

Regarding direct laparoscopic trans-parahepatic pericystostomy, the procedure was developed with the important advantages in mind, as it allows exclusion of peritoneal complications, and combines the indisputable advantages of laparoscopic techniques in terms of postoperative pain, length of stay, resumption of transit and eating, resumption of household activities or job and shortening the healing period.

This drainage technique of remaining liver cavities belongs in the category of external biliary drainage techniques, because most hepatic cysts associate one or more biliary fistulas, and hepatic abscesses that develop in the cavity of hydatid cysts are due to bile leakage and hydatid pump, or bile contents of the cyst, contaminated by biliary anaerobic flora that grow in conditions of stasis and anaerobiosis.

Surgical indication of the type of external biliary drainage of the remaining liver cavities involves selecting all remaining hepatic cavities located in the lateral or central liver segments, VIth, VIIth and VIIIth, and possibly Vth, successive of

hepatic hydatid cysts, sterile or infected, single or multiple liver abscesses, amoebic cysts or highly infected serous cysts, posttraumatic infected hematoma, biliary or congenital intrahepatic cysts, except the type of malignant lesions like cystadenocarcinomas or other hepatic cystic tumors.

Indication of surgical technique depends on the functional and pathological characteristics of each patient, associated diseases, age or other, the choice between classic or laparoscopic technique belonging to the department of anesthesia and intensive care, evaluating intraoperative surgical anesthetic conditions, tracking vital signs and anesthesia during surgery and the risks induced by pneumoperitoneum, especially the postoperative follow-up. Ideal for achieving the best results of this surgery is the laparoscopic technique.

Conclusions

Laparoscopic extraperitoneal transligamentary drainage of the residual hepatic cavity due to a hydatid and hepatic abscesses, with the same effect as the classic intervention, solves the problem of the residual cavity by placing an exteriorized cavity drain through the round ligament in such a way that this route is situated outside the peritoneal cavity, meaning it has no contact with this cavity.

Laparoscopic technique is different from the known classic technique and has a number of particularities and intermediate steps imposed by the principles of the laparoscopic surgery (different

from those used in the classic technique) and uses completely different instruments without affecting the principle of the method. To these a series of advantages are added that make the laparoscopic technique efficient, riskless and controversial (12, 13).

Regarding direct laparoscopic drainage, realizing the eventuality of this accession by symphysis between the liver and abdominal wall, we occasionally noticed during reintervention that the ideal process was a controlled sealing of the liver to the abdominal wall around the wound for a hepatic hydatid cyst located in right side of the hepatic segments, allowing the posthidatic remaining hepatic cavity to be drained externally.

Even though our analysis shows that laparoscopic procedures are still outnumbered by their classical counterparts, this is only due to strict limitations that emerge mainly from the anatomical positioning of the cyst rather than the technique itself. With precise details of how they should be applied, laparoscopic procedures, in our opinion, should always be considered, as they provide positive outcomes regarding patient recovery, shortening hospitalization time, and good acceptance by patients.

Acknowledgments:

This material is part of a larger study of a PhD thesis, currently under development by Rarinca (Moldovan) Diana-Adina, M.D., Ph. D. Student at

the Titu Maiorescu University of Bucharest, Faculty of Medicine with Prof. Ungureanu Florin Dan as thesis coordinator. All authors have read and approved the final manuscript and declare no conflicts of interest.

References

1. Turkcapar AG, Ersoz S, Gungor C, Aydinuraz K, Yerdel MA, Aras N. Surgical treatment of hepatic hydatidosis combined with perioperative treatment with albendazole. *The European journal of surgery* 1997; 163(12): 923-8.
2. Sever M, Skapin S. Laparoscopic pericystectomy of liver hydatid cyst. *Surgical endoscopy* 1995; 9(10): 1125-6.
3. Misra MC, Khan RN, Bansal VK, Jindal V, Kumar S, Noba AL, Panwar R, Kumar A. Laparoscopic pericystectomy for hydatid cyst of the liver. *Surgical laparoscopy, endoscopy & percutaneous techniques* 2010; 20(1): 24-6.
4. Ungureanu FD, Cucu S, Gadea A, Mihelis M, Mircea G, Dragomir R, Moldovan AC. Drenajul transomfalic extraperitoneal al cavitatii restante hepatice posthidatice pe cale laparoscopica. *Chirurgia* 2004; 99(3): 159-65.
5. Burlui D, Manescu G, Constantinescu C, Popescu R, Strutenski T. Transhepatic canal intubation in the surgery of the hepato-choledochal canal. *Annales de chirurgie* 1967; 21(21): 1271-3.

6. Bickel A, Daud G, Urbach D, Lefler E, Barasch EF, Eitan A. Laparoscopic approach to hydatid liver cysts. Is it logical? Physical, experimental, and practical aspects. *Surgical endoscopy* 1998; 12(8): 1073-7.
7. Guibert L, Gayral F. Laparoscopic pericystectomy of a liver hydatid cyst. *Surgical endoscopy* 1995; 9(4): 442-3.
8. Giuliante F, D'Acapito F, Vellone M, Giovannini I, Nuzzo G. Risk for laparoscopic fenestration of liver cysts. *Surgical endoscopy* 2003; 17(11): 1735-8.
9. Ungureanu FD, Daha C, Ungurianu L, Cucu S. Extraperitoneal transomphalic drainage of the posthydatid hepatic restant cavity by open and coelioscopic approach. *Proceedings of the EuroSurgery* 2002: 339-46.
10. Khoury G, Abiad F, Geagea T, Nabout G, Jabbour S. Laparoscopic treatment of hydatid cysts of the liver and spleen. *Surgical endoscopy* 2000; 14(3): 243-5.
11. Aktan AO, Yalin R. Preoperative albendazole treatment for liver hydatid disease decreases the viability of the cyst. *European journal of gastroenterology & hepatology* 1996; 8(9): 877-9.
12. Bickel A, Eitan A. The use of a large, transparent cannula, with a beveled tip, for safe laparoscopic management of hydatid cysts of liver. *Surgical endoscopy* 1995; 9(12): 1304-5.
13. Bickel A, Loberant N. The feasibility of safe laparoscopic treatment of hydatid cysts of the liver. *Surgical endoscopy* 1995; 9(8): 934-5.